

## CLINICAL AND MOLECULAR CHARACTERISTICS OF THAI PATIENTS WITH ACHONDROPLASIA

Vorasuk Shotelersuk<sup>1</sup>, Chupong Ittiwut<sup>2</sup>, Sumarlee Srivuthana<sup>1</sup>, Suthipong Wacharasindhu<sup>1</sup>, Suphab Aroonparkmongkol<sup>3</sup>, Apiwat Mutirangura<sup>2</sup> and Yong Poovorawan<sup>1</sup>

<sup>1</sup>Department of Pediatrics, <sup>2</sup>Department of Anatomy, Faculty of Medicine, Chulalongkorn University, Bangkok 10330, Thailand; <sup>3</sup>The Thai Red Cross, Bangkok 10330, Thailand

**Abstract.** Achondroplasia is an autosomal dominant disorder characterized by disproportionately short stature, frontal bossing, rhizomelia, and trident hands. Most patients appear sporadically resulting from a *de novo* mutation associated with advanced paternal age. A glycine to arginine mutation at codon 380 (G380R) of the fibroblast growth factor receptor 3 gene (*FGFR3*) was found to be the most common cause of achondroplasia in various populations. We identified and clinically characterized 3 Thai patients with achondroplasia. In all of them, we also successfully identified the G380R mutation supporting the observation that this is the most common mutation in achondroplasia across different ethnic groups including Thai.

### INTRODUCTION

Patients with short stature display an extremely long list of differential diagnoses. Achondroplasia is one of them. Clinical manifestations and molecular defects of patients with achondroplasia have been described in various ethnic groups. Here we report three Thai patients with achondroplasia whose molecular abnormalities were successfully identified, providing a specific method for molecular diagnosis of patients and for prenatal diagnosis in families at risk.

### MATERIALS AND METHODS

**Case reports:** Three patients coming to the Genetics Clinic at King Chulalongkorn Memorial Hospital were diagnosed with achondroplasia. Patient 1 was born at term to a 37 year-old G3P2 Thai mother and a 43 year-old unrelated Thai father. Neither the parents

Correspondence: Dr Vorasuk Shotelersuk, Head, Division of Genetics, and Metabolism, Department of Pediatrics, Sor Kor Building 11<sup>th</sup> floor, King Chulalongkorn Memorial Hospital, Bangkok 10330, Thailand.

Tel: (662) 256-4989; Fax: (662) 256-4911  
E-mail:fmdevst@md2.md.chula.ac.th

nor the two elder sisters of patient 1 were affected. Pregnancy and delivery were uncomplicated. His birth weight was 3,590 g (+1 SD), length 47 cm (-2 SD), and head circumference 38.5 cm (+3 SD). In addition to short stature, physical examination revealed increased upper to lower trunk ratio (2.2:1) (normal 1.7:1), frontal bossing, rhizomelia, trident hands, left hydrocele, and lordosis (Fig 1A). Achondroplasia was diagnosed soon after birth. At 8 months of age, his head circumference was 49 cm (+4 SD). Due to the rapid increase of his head size, a CT scan of the brain was performed revealing hydrocephalus. A ventriculoperitoneal shunt was placed. Developmental assessment by the Gesell Developmental schedule showed a developmental quotient of 73 at the chronological age of 1 year and 8 months. The left hydrocele was surgically repaired at 1 year and 9 months. Polysomnography performed at 2 years and 6 months was normal. At 4 years and 6 months, growth hormone provocative tests by insulin and clonidine showed maximum growth hormone levels of 1.9 and 6.4 ng/ml, respectively, indicating growth hormone deficiency. The IQ test by WISC III revealed verbal IQ, performance IQ and full IQ of 84, 103, 93 respectively at 8 years of age. Radiography of the lumbar spine showed caudal narrowing

of the spinal canal with short pedicles (Fig 2A). At his last follow-up at 8 years and 1 month, his height was 100.2 cm (-4 SD), weight 19.6 kg (-1 SD), and head circumference 56 cm (+2.5 SD).

Patient 2 was born at term to a 27-year-old G1P0 Thai mother and a 27-year-old unrelated Thai father. The parents were unaffected. Pregnancy, labor and delivery were unremarkable. His birth weight was 3,500 g and his length 47 cm. Physical examination at 4 months of age revealed macrocephaly with a head circumference of 43 cm (+2 SD), increased upper to lower trunk ratio (40:19.5 = 2.05:1), large anterior fontanel, frontal bossing, depressed nasal bridge, trident hands, and rhizomelia (Fig 1B). Radiography revealed decreased interpeduncular distances of his lumbar vertebrae. A diagnosis of achondroplasia was made. CT scan of the brain at 10 months revealed hydrocephalus requiring

ventriculoperitoneal shunt. Developmental assessment by the Gesell Developmental schedule showed a mental age of 39 weeks at the chronological age of 79 weeks. The IQ test according to Stanford Binet revealed an IQ of 82 at 5 years of age. Echocardiogram performed at 2 years and an eye examination at 3 years were unremarkable. Noisy breathing was developed at the age of 5 years. Obstructive sleep apnea was found by polysomnography and his hypertrophic tonsils and adenoids were removed at the age of 5 years and 10 months. The following tests were normal: blood cell counts, blood sugar, BUN, Cr, electrolytes, prothrombin time, and partial thromboplastin time. At his last visit at the age of 6 years and 10 months his height was 99.3 cm (-2.5 SD), weight 31.4 kg (+2.5 SD), and head circumference 54 cm (+1.5 SD).

Patient 3 was born at term after uncom-

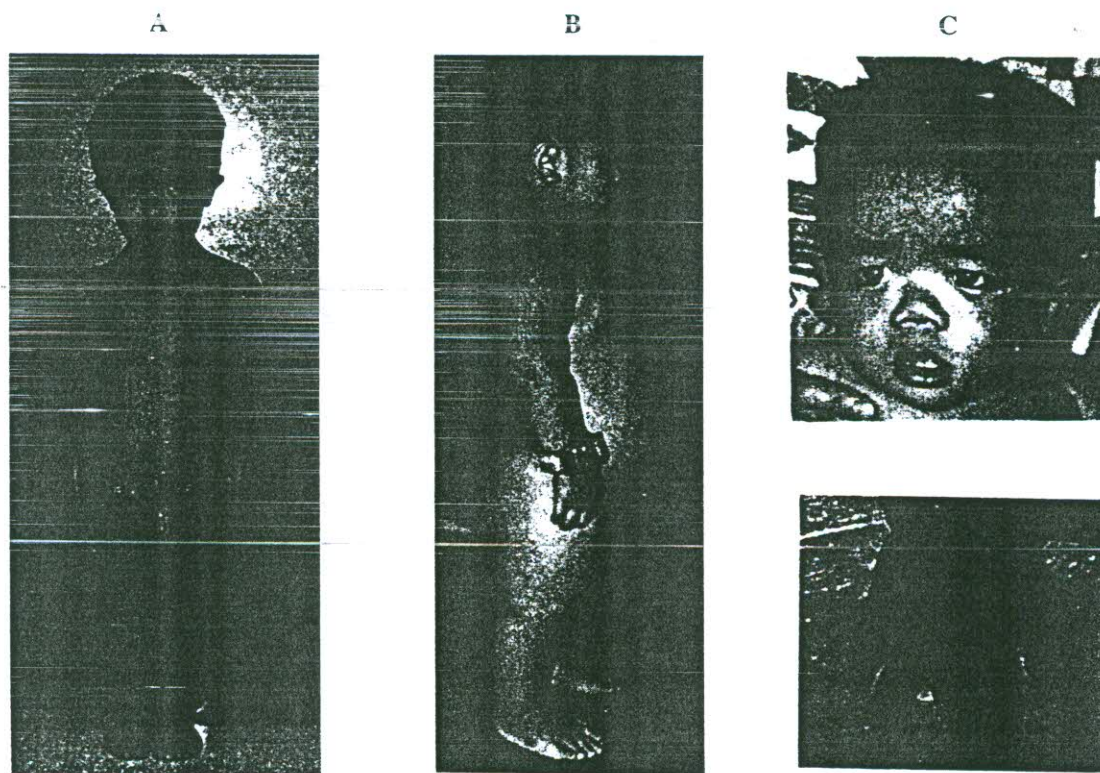


Fig 1—Clinical features. A. Patient 1 at 7 years of age showing disproportionate short stature with rhizomelia. B. Patient 2 at 6 years old revealing frontal bossing, overweight, and lumbar lordosis. C. Patient 3 at 11 months old showing maxillary hypoplasia (upper panel) and a trident hand (lower panel).

plicated pregnancy and delivery to a 36-year-old G3P2 Thai mother and a 39-year-old unrelated Thai father. Parents and the two elder siblings of patient 3 were unaffected. His birth weight was 3,400 g. Physical examination at the age of 11 months showed his weight at 6,900 g (-2.5 SD), length 62 cm (-5 SD), head circumference 47.5 cm (+2 SD), and arm span 58 cm. He had frontal bossing, midface hypoplasia, trident hands, kyphosis, and rhizomelia (Fig 1C). Developmentally, at 1 year of age, he could not sit unsupported but was able to do pincer grasp and talked a few words. Radiography of the spine revealed dextroscoliosis and narrowing of the interpeduncular distance of the lumbar vertebrae. Echocardiogram performed at 1 year of age was normal. CT scan of the brain at 1 year of age showed communicating hydrocephalus requiring lumboperitoneal shunt placement (Fig 2B).

#### Mutation analysis

After informed consent was obtained in accordance with the standards set by local institutional review boards, 6 ml of peripheral blood were obtained for DNA isolation by a standard method. *FGFR3* exon 10 was PCR amplified using the following two primers: 5' CTC TGG GCC AGG GGA ATC CAT 3' and 5' GGCTGC AGA GAG GGC TCA CAC 3'. The PCR conditions were 30 seconds at 94°C and 90 seconds at 68°C for 35 cycles. The PCR products were digested with *SfcI* according to the manufacturer's specifications and electrophoresed on a 2% agarose gel (Promega) stained with ethidium bromide on preparation.

#### RESULTS

The PCR amplification was used to generate a 372 bp fragment. The 1138G→A transition of the *FGFR3* gene creates an *SfcI* restriction site. Hence, in the mutant allele, the 372 bp product is cleaved by *SfcI* into 234, 131 and 7 bp fragments. After digestion with *SfcI*, the PCR products of all three patients yielded 3 bands of 372, 234 and 131 bp. The expected

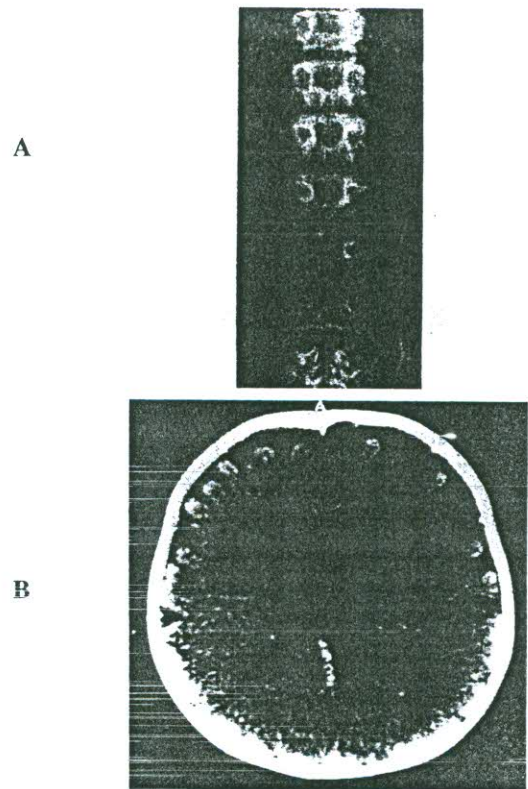


Fig 2—Imaging. A. Radiograph of lumbar spine of patient 1 at 7 years of age revealing caudal narrowing of the spinal canal and a shadow of a ventriculoperitoneal shunt. B. CT scan of the brain of patient 3 at 11 months old revealing hydrocephalus.

7 bp band could not be seen due to its small size. These results indicated that all of them were heterozygous for the 1138G→A transition.

#### DISCUSSION

Achondroplasia (MIM 100800), is the most common form of short-limbed dwarfism in humans. Its prevalence is estimated to be 1 in 20,000 (Stoll *et al*, 1989). The physical features evident at birth include frontal bossing, midface hypoplasia, rhizomelia, trident hands, genu varum, limitation of elbow extension, and exaggerated lumbar lordosis (Hall, 1992). The characteristic radiological features include caudal narrowing of the interpedicular distance (Oberklaid *et al*, 1979). We found

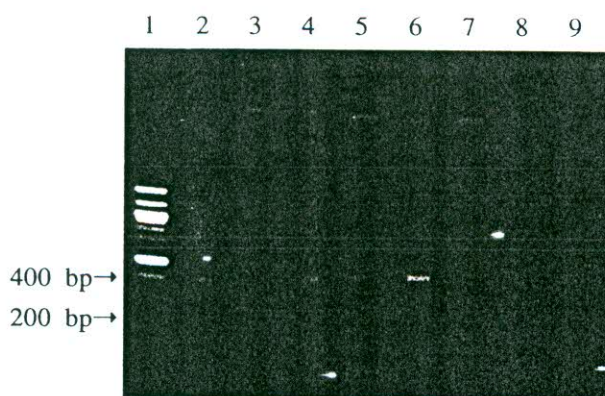


Fig 3—Restriction enzyme detection of the G380R mutation in achondroplasia. Lane 1 represents a 100 bp marker with the bands at 200 and 400 bp indicated with arrows. Lanes 2 and 3 were of the mother of patient 1; lanes 4 and 5 patient 1; lanes 6 and 7 patient 3; lanes 8 and 9 the mother of patient 3. Lanes 2, 4, 6 and 8 were PCR products without adding restriction enzymes and only the undigested 372 bp bands were presented. Lanes 3, 5, 7, and 9 were PCR products mixed with *SfcI*. The new bands of 231 bp and 134 bp in lanes 5 and 7 demonstrate that these individuals are heterozygous for the 1138G→A mutation. The products of their mothers in lane 3 and 9 were not cleaved by *SfcI*, which serves as negative controls.

3 patients with features typical for achondroplasia. In addition, they all have hydrocephalus requiring shunt placement to decrease the intracranial pressure. Ventriculomegaly in achondroplastic children was shown to accompany hydrocephalus, which is likely secondary to increased intracranial venous pressure due to hemodynamically significant stenosis of the jugular foramen and jugular venous obstruction at the level of the thoracic inlet (Steinbok *et al*, 1989). Patient 2 also had obesity. Obesity has been shown to be a significant health problem in achondroplasia (Hecht *et al*, 1988). Weight should be closely monitored and dietary intervention instituted whenever patients are overweight (American Academy of Pediatrics Committee on Genetics, 1995). All of our patients displayed noisy breathing, which is one of the known complications in achondroplasia (Stokes *et al*, 1983). Although delayed in early motor development, all of our patients showed intel-

ligence within the normal range, consistent with most achondroplasia patients (Brinkmann *et al*, 1993).

Genetically, achondroplasia is inherited in an autosomal dominant fashion with complete penetrance (Tanaka, 1997). Eighty to 90% of cases are sporadic and associated with advanced paternal age (Stoll *et al*, 1989). After the gene had been cloned, molecular work has confirmed that mutations of the *FGFR3* gene in sporadic cases of achondroplasia occur exclusively on the paternally derived chromosome (Wilkin *et al*, 1998). All of our three achondroplasia patients are sporadic cases. The paternal ages of patients 1 and 3 were advanced (43 and 39 years).

Molecularly, the gene responsible for achondroplasia has been mapped to chromosome 4p16.3 (Velinov *et al*, 1994; Le Merrer *et al*, 1994; Francomano *et al*, 1994). Shortly after the gene had been mapped, the mutation of the fibroblast growth factor receptor-3 (*FGFR3*) gene was identified (Shiang *et al*, 1994; Rousseau *et al*, 1994). More than 99% of achondroplasia is caused by an *FGFR3* G380R mutation. Bellus *et al* (1995) found that 150 out of 154 unrelated patients showed the 1138G→A transition and 3 the 1138G→C transversion. Achondroplasia patients of other ethnic groups including Swedes, Chinese, Japanese, Jews and Arabs also have the most common mutations resulting in the G380R (Alderborn *et al*, 1996; Niu *et al*, 1996; Tanaka, 1997; Passos-Bueno *et al*, 1999; Katsumata *et al*, 2000; Falik-Zaccari *et al*, 2000). This study revealed that Thai achondroplasts also had the 1138G→A transition resulting in G380R as the most common mutation. Even though the patients are all sporadic reducing the recurrence risk to far below 50% in younger siblings of the patients, the risk is not negligible. Owing to advanced molecular techniques, a powerful method to perform prenatal diagnosis is now available to the parents.

In summary, we have identified three unrelated Thai patients with achondroplasia. They all display the 1138G→A mutation of the *FGFR3* gene supporting the observation

that this is the most common mutation responsible for the phenotype across different populations.

## ACKNOWLEDGMENTS

The authors wish to thank the patients and their families for their cooperation and Ms Apiradee Theamboonlers for her excellent technical work. This work was supported by the Molecular Biology Project, Faculty of Medicine, the Development Grants for New Faculty/Researchers, Chulalongkorn University and the Thailand Research Fund: contract grant number: RSA/05/2544. We also thank Ms Petra Hirsch for editing the manuscript.

## REFERENCES

- Alderborn A, Anvret M, Gustavson KH, Hagenas L, Wadelius C. Achondroplasia in Sweden caused by the G1138A mutation in *FGFR3*. *Acta Paediatr* 1996; 85: 1506-7.
- American Academy of Pediatrics Committee on Genetics. Health supervision for children with achondroplasia. *Pediatrics* 1995; 95: 443-51.
- Bellus GA, Hefferon TW, Ortiz de Luna RI, et al. Achondroplasia is defined by recurrent G380R mutations of *FGFR3*. *Am J Hum Genet* 1995; 56: 368-73.
- Brinkmann G, Schlitt H, Zorowka P, Spranger J. Cognitive skills in achondroplasia. *Am J Med Genet* 1993; 47: 800-4.
- Falik-Zaccari TC, Shachak E, Abeliovitch D, et al. Achondroplasia in diverse Jewish and Arab populations in Israel: clinical and molecular characterization. *Isr Med Assoc J* 2000; 2: 601-4.
- Francomano CA, Ortiz de Luna RI, Hefferon TW, et al. Localization of the achondroplasia gene to the distal 2.5 Mb of human chromosome 4p. *Hum Mol Genet* 1994; 3: 787-92.
- Hall BD. Approach to skeletal dysplasia. *Pediatr Clin North Am* 1992; 39: 279-305.
- Hecht JT, Hood OJ, Schwartz RJ, Hennessey JC, Bernhardt BA, Horton WA. Obesity in achondroplasia. *Am J Med Genet* 1988; 31: 597-602.
- Katsumata N, Mikami S, Nagashima-Miyokawa A, et al. Analysis of the *FGFR3* gene in Japanese patients with achondroplasia and hypochondroplasia. *Endocr J* 2000; 47 (Suppl): S121-4.
- Le Merrer M, Rousseau F, Legeai-Mallet L, et al. A gene for achondroplasia-hypochondroplasia maps to chromosome 4p. *Nat Genet* 1994; 6: 318-21.
- Niu DM, Hsiao KJ, Wang NH, Chin LS, Chen CH. Chinese achondroplasia is also defined by recurrent G380R mutations of the fibroblast growth factor receptor-3 gene. *Hum Genet* 1996; 98: 65-7.
- Oberklaid F, Danks DM, Jensen F, Stace L, Rosshandler S. Achondroplasia and hypochondroplasia. Comments on frequency, mutation rate, and radiological features in skull and spine. *J Med Genet* 1979; 16: 140-6.
- Passos-Bueno MR, Wilcox WR, Jabs EW, Sertie AL, Alonso LG, Kitoh H. Clinical spectrum of fibroblast growth factor receptor mutations. *Hum Mutat* 1999; 14: 115-25.
- Rousseau F, Bonaventure J, Legeai-Mallet L, et al. Mutations in the gene encoding fibroblast growth factor receptor-3 in achondroplasia. *Nature* 1994; 371: 252-4.
- Shiang R, Thompson LM, Zhu YZ, et al. Mutations in the transmembrane domain of *FGFR3* cause the most common genetic form of dwarfism, achondroplasia. *Cell* 1994; 78: 335-42.
- Steinbok P, Hall J, Flodmark O. Hydrocephalus in achondroplasia: the possible role of intracranial venous hypertension. *J Neurosurg* 1989; 71: 42-8.
- Stokes DC, Phillips JA, Leonard CO, et al. Respiratory complications of achondroplasia. *J Pediatr* 1983; 102: 534-41.
- Stoll C, Dott B, Roth MP, Alembik Y. Birth prevalence rates of skeletal dysplasias. *Clin Genet* 1989; 35: 88-92.
- Tanaka H. Achondroplasia: recent advances in diagnosis and treatment. *Acta Paediatr Jpn* 1997; 39: 514-20.
- Velinov M, Slaugenhaupt SA, Stoilov I, Scott CI Jr, Gusella JF, Tsipouras P. The gene for achondroplasia maps to the telomeric region of chromosome 4p. *Nat Genet* 1994; 6: 314-7.
- Wilkin DJ, Szabo JK, Cameron R, et al. A. Mutations in fibroblast growth-factor receptor 3 in sporadic cases of achondroplasia occur exclusively on the paternally derived chromosome. *Am J Hum Genet* 1998; 63: 711-6.